

Retinopathy at High Altitude and other Ocular Changes

Manjit Singh Boparai

Emeritus Professor, NAMS (India),
Former Director General Medical Services (Air) and
Director/Professor of Ophthalmology,
Armed Forces Medical College, Pune

ABSTRACT

Retinal haemorrhages in mountain climbers have been reported from time to time and their incidence has varied in different studies. The results are based on the observations made in small number of members taking part in expeditions. We studied this aspect as large number of troops were inducted in high altitude areas during sixties and seventies. Studies were carried out on 250 healthy soldiers in the age group 25-45 years, inducted to a Himalayan station located at an altitude of 11550 feet. They underwent fundus examination on dilated pupils and relevant ocular parameters like, visual acuity, colour vision, tonometry and ophthalmodynamometry were carried out. They were then dispatched to pickets at altitudes varying from 12000 to 16000 feet. Seventy personnel developing symptoms of high altitude pulmonary oedema (HAPO) underwent fundus examination that showed 15 cases (21.4%) with papilloedema, all had venous engorgement, and 40 cases (57.1%) showed flame shaped superficial haemorrhages around the disc and mid periphery of retina. Haemorrhages resolved fully in 4-6 weeks. Asymptomatic personnel underwent fundus examination at 3-4 month intervals and on deinduction. Thirty of them (16.6%) had superficial haemorrhages scattered in the background but they had no symptoms of any kind. Observations have been discussed in the light of other studies and literature has been reviewed.

Keywords : High altitude, hypoxia, mountain sickness, retinopathy.

Correspondence : Air Marshal (Dr.) Manjit Singh Boparai, 915, Sector-17B, Gurgaon-122001 (Haryana)

Introduction

The environmental factors having role in high altitude disorders are reduced barometric pressure causing reduction in partial pressure of oxygen (Hypoxia), severe cold, low humidity, strong winds and increased solar radiation. Systematic studies on high altitude problems started after induction of large numbers of troops in high altitude areas in India in late sixties and early seventies. First report of changes in retina by way of haemorrhages, now more holistically called retinopathy were by Singh *et al* in cases of acute mountain sickness (AMS) (1). In an earlier study by Menon, wherein he presented clinical data of 101 cases of HAPO there is no mention of any ocular changes (2) There have also been studies on various aspects of high altitude retinopathy on limited number of members of mountaineering expeditions in Himalayan and South American mountains (3-7). Following the induction of Indian troops in high altitude areas observations on retinopathy based on study of larger numbers have been made by Sharma (8), Goswami (9) and Gupta (10). The study being reported is on follow up of 250 army personnel who were operating at altitude varying from 12000 to 16000 feet.

Material and Methods

Two hundred and fifty soldiers in the age group 25-45 years were inducted by air/ road in a northern Himalayan station at an altitude of 11550 feet. They were examined within a week of their arrival for visual acuity, colour vision, field of vision and intraocular pressure (IOP). Fundoscopy and ophthalmodynamometry were also undertaken. Fundus examination was carried out on dilated pupils. After varying periods of stay (2-3 weeks) at this altitude, they were transported or marched to outposts by surface route. Those with any retinal pathology were not included in the study.

The soldiers who developed effects of high altitude by way of HAPO were examined for the above parameters but more particularly for retinal vascular changes. Others were examined either if they reported with any visual and other symptoms or otherwise after interval of 3-4 months for one and a half years.

Observations

1. Two hundred soldiers were inducted by air and fifty by road. Seventy soldiers (37.5%) of those inducted by air complained of light headedness, lack of sleep, mild breathlessness and episodes of blurred vision lasting upto 5

seconds. These were transient and disappeared in 3-4 days. Those induced by road did not suffer from these transient effects.

2. Fundus examination of 70 cases of HAPO revealed:

- (a) Early papilloedema in 15 cases (21.4%) (Fig. 1).
- (b) Engorged veins in all cases (Fig. 2).
- (c) Superficial flame shaped retinal haemorrhages around disc and mid periphery were seen in 40 cases (57.1%). In 4 cases superficial haemorrhages were extensive becoming pre-retinal (Fig. 3-5).
- (d) One case was found to have a branch retinal vein occlusion

involving supero-temporal branch (Fig. 6).

- (e) No case in this study had macular and vitreous haemorrhage,

3. With improvement in general condition, disc oedema, venous engorgement, and retinal haemorrhages recovered fully in 4-6 weeks.

4. Examination of the 180 asymptomatic personnel revealed that 30 (16.6%) had scattered flame shaped and splinter haemorrhages in various stages of absorption and some neovascularisation. These personnel had been operating at altitudes above 14000 feet for periods varying from 6 months to one year.

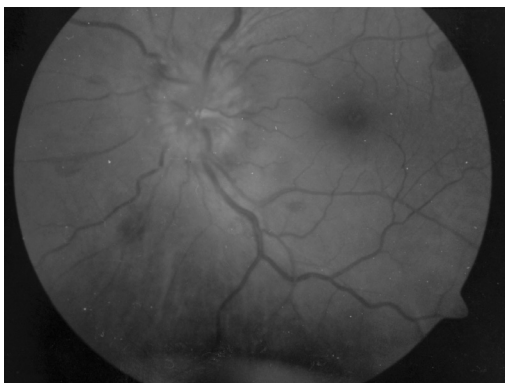

Fig. 1 : Fundus photograph showing papilloedema, haemorrhages and venous engorgement.

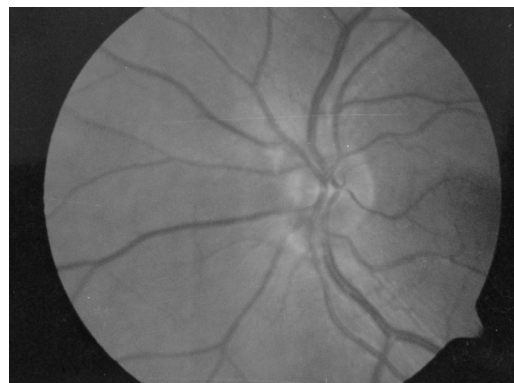


Fig. 2 : Fundus photograph showing dilatation of retinal vasculature

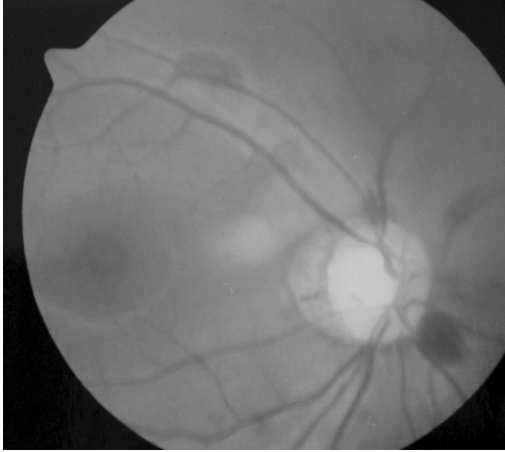

Fig. 3 : Fundus photograph showing peripapillary haemorrhages

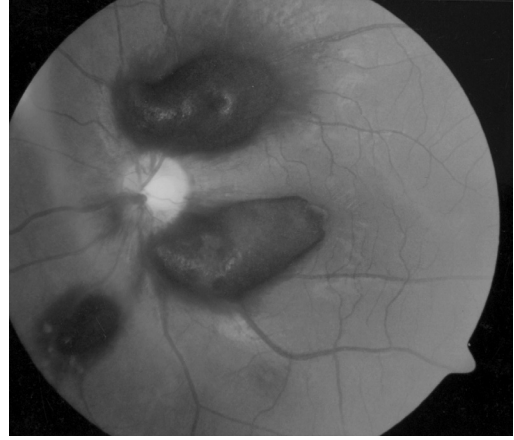


Fig. 5 : Fundus photograph showing extensive pre-retinal haemorrhages.

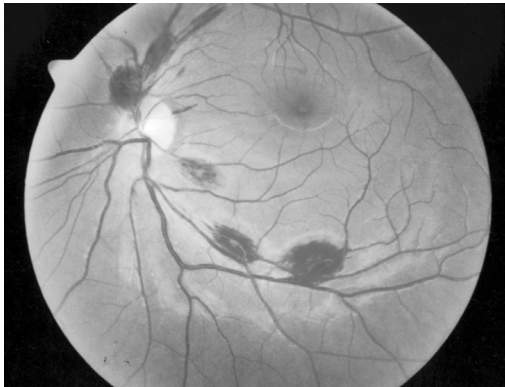


Fig. 4 : Fundus photograph showing scattered flame shaped haemorrhages in mid periphery

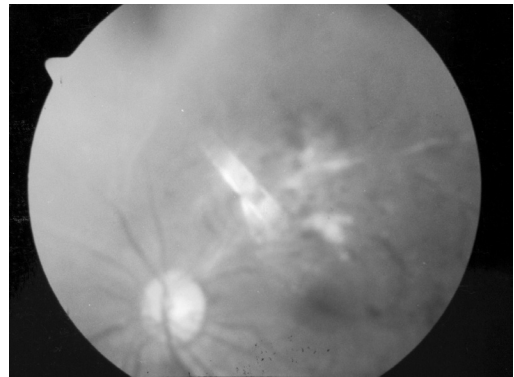

Fig. 6 : Fundus photograph showing branch retinal vein occlusion and neovascularisation.

5. IOP in all cases varied between 15-22 mm Hg by Schiottz tonometer on induction as well as on re-examination. However, 5 cases of glaucoma that were well controlled with 1-2% Pilocarpine drops

went out of control and had to be evacuated to lower heights where the pressure got controlled on the same therapy.

6. No change in colour vision was recorded in any case.

7. Ophthalmodynamometry in non-symptomatic personnel showed the systolic pressure of central retinal artery between 60-100 mm Hg and diastolic between 35-60 mm Hg on initial as well as re-examination indicating rise in retinal arterial pressure.

Discussion

Transient effects of high altitude were found in those inducted by air. Those inducted by road did not have these effects indicating the beneficiary role of gradual climb and acclimatization. Similar observations have been made by Sharma and Goswami (8, 9).

The incidence of papilloedema (21.4%) in this study is much more than 1.2% reported by Singh et al.(1) It is possibly due to the fact that they had reported their findings in cases of AMS only. Their cases had not gone to the stage of HAPO but our observations are in cases of HAPO. Frayser et al also noticed papilloedema in cases who were more severely affected than others (3).

Incidence of retinal haemorrhages of 57.1% in this study is fairly high. The incidence in various studies has varied from 1.3% to 66%. Singh et al 1.3% (24 cases out of 1925) (1), Frayser et al 36% (9 cases out of 25)(3), Mc Fadden et al 56% amongst 39 climbers(6)

and Shults and Swan 66% (4 out of 6 survivors of the ill fated Aconcagua expedition)(5). In a later study, Butler et al in their 14 Everest climbers found the incidence to be 29% which is on the lower side(7). Climbers in their study had followed a regime of gradual ascent with rest stops. This highlights the role of acclimatization in bringing down the incidence of retinopathy and other effects of high altitude. Another possible reason for these variations could be the varying parameters of climb and divergent conditions of ascent and exercise levels in different studies.

Pathophysiology of retinopathy is difficult to explain on any one single factor and is possibly multifactorial. Ocular and systemic blood pressures increase in high altitude sickness (11). Ophthalmodynamometry readings in our study have also shown rise in retinal arterial pressures. Hypobaric hypoxia results in reduction of partial pressure of oxygen from normal 95 mm Hg at sea level to approximately 60 mm Hg at 16000 feet. Drop in oxygen available to meet the body's metabolic requirements sets in motion a number of physiological processes such as increased cardiac output and minute ventilation. Frayser et al have shown that retinal blood flow increases producing clinically observable changes

of increase in diameter and tortuosity of retinal vasculature (4). Capillary fragility has also been shown to increase (12). All these factors put together set the stage for retinopathy to take place. Additionally increased CSF pressure, causing effusion of CSF into the optic nerve sheath results in compression of retinal veins and papilloedema. Valsalva maneuver required during climbing and haematocrit changes may be further aiding development of retinopathy. Individual susceptibility may also be a factor.

IOP in our study does not seem to vary much at altitude. Subsequent study by Gupta shows the same (10). However, study by Sharma has shown a slight fall in IOP (8). Destabilization of glaucoma cases under treatment shows that possibly aqueous outflow might be getting compromised. Variations in corneal thickness due to cold and solar radiation may have some role also. More studies are required on this aspect.

Conclusions

Retinopathy is a definite accompaniment of changes induced by hypoxia and reduced barometric pressure at high altitude and is a reversible condition. Pathophysiology of retinopathy is multifactorial. Incidence

is variable and has been coming down with acclimatization.

Acknowledgement

Help rendered by Lt Col SS Mann in preparing this paper is gratefully acknowledged.

References

1. Singh I, Khanna PK, Srivastava MC, et al (1969). Acute mountain sickness. *N Engl J Med* **280**:175-184.
2. Menon ND (1965). High altitude pulmonary oedema : A clinical study. *N Engl J Med* **273**:66-73.
3. Frayser R, Houston CS, Bryan AC, et al (1970). Retinal haemorrhages at high altitude. *N Engl J Med* **282**: 1183-1184.
4. Frayser R, Houston CS, Gray GW, et al (1971). The response of the retinal circulation to altitude. *Arch Intern Med* **127**:708-711.
5. William T Shults, Kenneth C Swan (1975). High altitude retinopathy in mountain climbers. *Arch Ophthalmol* **93**:404-408.
6. McFadden DM, Houston CS, Sutton JR, et al (1981). High altitude retinopathy. *JAMA* **245**:581-586.
7. Butler FK, Harris DJ and Reynolds

- R (1992). Altitude retinopathy on Mount Everest, 1989. *Ophthalmology* **99**:739-746.
8. Sharma RC (1981). Ocular manifestations of high altitude. *Indian J Ophthalmol* **29**:261-262.
 9. Goswami BL (1984). High altitude retinal haemorrhages. *Indian J Ophthalmol* **32**: 321-324.
 10. Gupta RP, Srivastava SK, and Mishra MP (1993). Changes in retina in patients of high altitude pulmonary oedema. *Indian ophthalmology Today; Proceedings 51st Conf. All India Ophthalmological Society*: 354-356.
 11. Dill DB (1968). Physiological adjustments to altitude changes. *JAMA* **205**:747-753.
 12. Hunter DJ, Smart JR and Whitton L (1986). Increased capillary fragility at high altitude. *Br Med J* **292**:298.